L.T.I. CARBON PERMUCOSAL DENTAL IMPLANTS

A. Norman Cranin, D.D.S., Director
Michael F. Rabkin, D.D.S., Asst. Prosthodontist and Implantologist
Howard Silverbrand, D.D.S., Fellow, Implantology
Samuel Unger, D.D.S., Asst. Prosthodontist and Implantologist
Department of Dental and Oral Surgery
The Brookdale Hospital Medical Center
Brooklyn, New York 11212

and

Jack E. Armitage, D.D.S. Assoc. Professor of Oral Pathology
Michael Meenaghan, D.D.S., Assoc. Professor of Oral Pathology
University of Buffalo
School of Dentistry
Buffalo, New York 14214

The specific objectives of this research were the:

1. Evaluation of L.T.I. carbon implant-tissue interface at the osseous and gingival levels as a function of time.

2. Evaluation of clinical, radiographic and histologic aspects of implant-host site environment.

A. Methods and Materials

Pyrolytic isotropic carbon were used as the material of choice. It was applied to cores of graphite by alloying vapor deposited carbon with silicon over a steady state fluidized bed [1]

The design of the implants were that of a basic blade of approximately 2.0 mm bucco-lingual width, two infrastructural fenestrations, a grossly matte finished surface with a highly polished 2.0 mm cervical band and a permucosal abutment suitable for the application of a fixed retainer.

B. Implantation

One porous carbon coated blade implant was placed in each dog hemimandible so that permucosal sites for later evaluation resulted. Pericervical permucosal portions of the implant were highly polished to offer surrounding gingiva a hygienic environment. Seventeen hemimandibles were used for implantation and a schedule for edentulation-implantation and sacrifice was closely followed.

Evaluation

A. Clinical Evaluation

A schedule for both clinical and radiographic observation were followed. The animals were observed on a bi-monthly basis and lateral as well as occlusal radiographs taken of each hemimandible.

Radiographic changes such as crestal bone resorption, pericervical saucerization, architectural alterations and increase in peri-implant radiolucency (capsule thickness) were noted monthly.

B. Microscopic Evaluation

After sacrifice and perfusion of each animal with 10% formalin, mandibular block osteotomies yielded specimens of the implant-bone soft tissue complexes. These were studied in both hard tissue and decalcified forms.

Surgical Technique

Using a surgical air turbine under sterile coolant, an osteotomy was cut to the width of a #701 L surgical bur and sufficiently deep to accept the implant passively to the depth of the polished cervix.

Results

Clinical Findings

A major difference was noted between the large and small dogs. The animals in the under 10 kg. weight group had implants which showed varying levels of mobility with marked pocket formation, gingival hemorrhage and some hyperplasia. One implant was so mobile that its removal was warranted.

In the larger group, firmness of the implants was a constant characteristic. Pocket formation was minimal to moderate and healthy, non hemorrhagic gingiva was the rule. Whether or not fixed prostheses were applied, the clinical observations did not vary.

Radiographic Findings

Some saucerization (up to 2 mm) was noted in the small animals but little or none was found in the mandibles of the larger dogs. In most the larger animals, a clear-cut lamina dura was identifiable surrounding the implants.

Histology

A variety of histologic techniques were employed by groups at Tulane University [2] and the University of Buffalo. [3]

Two major groups were recognized - the large dogs which presented generally good to excellent findings and the small ones which met with universally unsatisfactory results.

The latter group offered evidence of epithelial downgrowth, acute inflammatory response, widened connective tissue capsules with fibers in parallel configurations to the implants.

The group of large animals on the other hand, for the most part presented from slight to moderate epithelial downgrowth. The coronal-most connective tissue fibers were often attached to or adherent to the implant and were sometimes oriented in a horizontal to oblique direction. Little or no inflammation was seen and consistent areas of osseous bridging offered evidence of viable bone. Connective tissue capsules present when bone was found not to be butting directly against carbon offered evidence of osteoid or new bone formation within them and in one instance periosteal like tissues and an osteoblast were found at the tissue-implant interface. There was not a trend toward catabalic change directly related to implant time in-situ.

Summary and Conclusion

1. Small dogs, having small mandibles, did not fare as well as their heavier counterparts.

2. Because of the natural radiolucence of silicon alloyed L. T. I. carbon implants on graphite matrices, customarily accepted radiographic interpretations were not as profound as with classically radiopaque implant materials.

3. By comparison to metallic implants of similar times in place [4] the amount of epithelial proliferation, pocket formation and hyperplasia surrounding L. T. I. carbon implants was surprisingly little. After 14 months of implant study with bridges no significant difference was noted as compared to those without bridges.

4. L. T. I. carbon appears to have osteogenetic potential when placed in bone. .

5. Because of the polished cervix of pyrolite endosteal implants, a high level of gingival health is promoted.

6. The irregular surface of these implants at the infrastructural level appears to be responsible for an intimate relationship of oblique or horizontal connective tissue fibers and on occasion even direct bone opposition. L. T. I. carbons modulous of elasticity, so close to that of bone, is probably responsible for minimal osseous host-site change.

This report describes the use of low temperature isotropic carbon dental implants, finds them to be more successful than metallic implants studied under comparable conditions and indicates promise for them as abutments for fixed prostheses.

References

1. Bokros, J. C. in Chemistry and Physics of Carbon, Vol. 5 (P. L. Walker, ed.) Dekker. New York, 1969, Chapter I.

2. Klawitter, J. J. Research techniques for evaluating tissue growth within porous materials, Paper presented at a Symposium-Workshop in Research Techniques in Biomaterials Evaluation, Clemson University, Clemson, S. C. 1971

3. Armitage, J. and Meenahan, M. Personal Communication re: the use of the Jung-Model K power driven microtone and histologic techniques for implant evaluation, Feb. 1977.

4. Schnitman, P. Thesis for masters degree - Dental Implants in Beagle Dogs - In preparation, 1971-1972.



L. T. I. Carbon Dental Implants

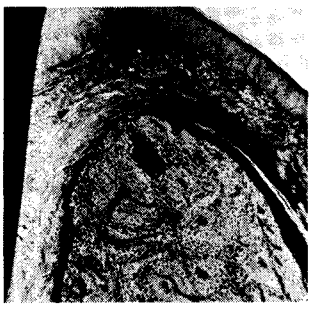

Soft Tissue - Implant Interface

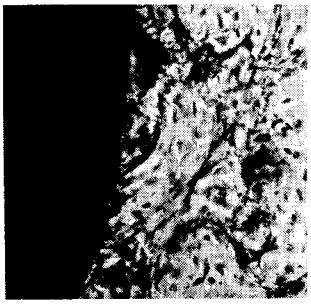

Bone - Implant Interface